

Does the Use of Blocking Screws Improve Radiological Outcomes Following Intramedullary Nailing of Distal Tibia Fractures?

Ross A Fawdington¹, Naeil Lotfi², Alastair Beaven³, Paul Fenton⁴

ABSTRACT

Aim: The aim of this study is to assess whether the addition of blocking screws during intramedullary nailing of a distal tibia fracture improved the radiological outcome and prevented a loss of fracture alignment. As a secondary outcome, the time to radiographic union was compared to see if a more rigid bone-implant construct had an effect on healing.

Methods: We searched computerized records at a UK level 1 major trauma center. The joint alignment was measured on the immediate postoperative radiograph and compared to the most recent radiograph. We used a difference of 2° to indicate a progressive deformity.

Results: Thirty patients were included. Twenty patients had no blocking screw and 10 patients had a blocking screw. Six patients had a difference in their coronal plane alignment of 2° or more (3/6 had no blocking screw). The results were analyzed and found to be not statistically significant ($p = 0.82$). The addition of a blocking screw has also been shown not to have an effect on the time to radiological union (RUST score greater or equal to 10).

Conclusion: We use a 2.5-mm blocking wire to aid in fracture reduction prior to reaming or nail insertion and then remove the wire when the nail has been adequately locked. We no longer routinely replace the wire with a blocking screw and this could lead to a decrease in procedure time, cost, and radiation exposure.

Keywords: Blocking screw, Deformity, Intramedullary nailing, Poller screw, Tibia.

Strategies in Trauma and Limb Reconstruction (2019); 10.5005/jp-journals-10080-1418

INTRODUCTION

Distal tibia fractures remain challenging injuries to treat. They can be managed with a variety of different fixation methods although the optimum technique is unclear.¹ Intramedullary nailing for fixation of distal tibia fractures has many potential benefits including less risk of soft tissue complications compared with plate fixation but malunion following nailing remains a concern.^{2,3} In a systematic review of 1,125 distal tibia fractures treated with an intramedullary nail, the reported incidence of malalignment was 14%.⁴

The use of blocking (or Poller) screws in the management of metaphyseal tibia fractures was first described by Krettek et al.⁵ They described the use of screws on the concave side of the fracture deformity to narrow the width of the medullary cavity in metaphyseal bone and thereby improve fracture reduction and increase the mechanical stability of the bone-implant construct. The blocking screw supplies the third point of stabilization, with the other two being the isthmus of the bone and the locking bolts at the end of the nail.⁶ Blocking screws can be used in a number of ways; they may be inserted before the canal is reamed to ensure that the reamed channel is in the center of the bone, they may be inserted after reaming but before nail insertion to centralize the nail on insertion or alternatively they may be inserted after the nail is placed to increase the construct stability.⁷

Although multiple cohort studies describe the use of blocking screws in metaphyseal fractures, there is little evidence to demonstrate improved clinical outcomes following their use, particularly with newer generation-locked intramedullary nails with multi-planar locking bolt options. The purpose of this study is to assess whether the addition of blocking screws to the bone-implant construct during intramedullary nailing of a distal tibia fracture

^{1–4}Department of Trauma and Orthopaedic, Queen Elizabeth Hospital Birmingham, Mindelsohn Way, Birmingham, UK

Corresponding Author: Ross A Fawdington, Department of Trauma and Orthopaedic, Queen Elizabeth Hospital Birmingham, Mindelsohn Way, Birmingham, UK, Phone: +44 121 371 2000, e-mail: fawdy@doctors.org.uk

How to cite this article: Fawdington RA, Lotfi N, Beaven A, et al. Does the Use of Blocking Screws Improve Radiological Outcomes Following Intramedullary Nailing of Distal Tibia Fractures? *Strategies Trauma Limb Reconstr* 2019;14(1):11–14.

Source of support: Nil

Conflict of interest: None

improved the radiological outcome and maintained the fracture alignment. As a secondary outcome, the time to radiographic union was compared between the two groups to see if a more rigid bone-implant construct had an effect on healing time.

METHODS

We performed a search of computerized hospital records at a UK level 1 major trauma center to identify patients undergoing intramedullary nailing of distal tibia fractures. Procedures performed between 1 January 2014 and 31 December 2016 were included (2 years). Patients that had either an intramedullary nail or an intramedullary nail and a blocking screw were included. All fractures were stabilized with an Expert Tibial Nail (Synthes, Switzerland). The decision to use blocking screws was made at the discretion of the senior surgeon involved and all procedures were either performed by a consultant or directly supervised by a consultant. Blocking

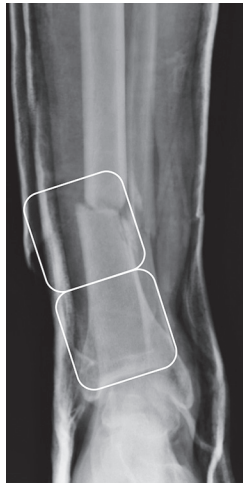

Fig. 1: An AP radiograph taken at the time of injury demonstrating a distal tibia fracture within 2 Müller squares

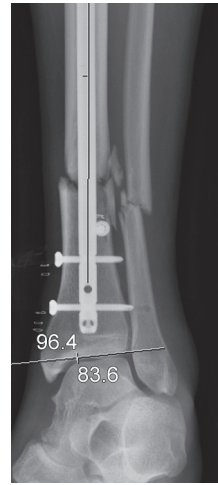


Fig. 2: An AP radiograph taken immediately postoperative with the joint angle measured

screws were either inserted before reaming or immediately prior to nail insertion. Preoperative radiographs were used to assess the fracture configuration. We included fractures that extended within 2 Müller squares of the tibial plafond (Fig. 1), and fractures that did not extend within 2 Müller squares or involve the distal metaphysis were excluded. The immediate postoperative radiographs were assessed for all patients, the alignment of the fracture was assessed using the method described by Paley (Fig. 2).⁸ The anatomical axis of the tibial diaphysis was compared to the tibial plafond angulation on the coronal and sagittal views. The measurement process was repeated on the most recent radiograph and the difference in angulation ("joint orientation difference") between the immediate postoperative radiograph and the alignment at the most recent radiograph was calculated (Fig. 3). We used a joint orientation difference of 2° or more to be indicative of a progressive deformity and a loss of fracture alignment.

Union was defined as a Radiological Union Scale for Tibia (RUST) score of 10 or more.⁹ The RUST score is a fracture assessment tool that was developed to help standardize the radiographic assessment of tibial fractures. This score assesses cortical bridging, which has been shown to correlate with the biomechanical strength

of the fracture site.¹⁰ We defined time to union as the period from injury, to the time of the first radiograph with a RUST score of 10 or more. Radiological assessment of joint orientation and union was performed by a single author (RF) to eliminate any interobserver error.

Statistical analysis was performed to compare the joint orientation difference (deformity/no deformity) between the blocking screw group and the no blocking screw group using the Chi-squared test. The number of distal locking bolts was treated as categorical data and compared between the two groups (deformity/no deformity) using a Chi-squared test. The time to union was normally distributed and the blocking screw group and the no blocking screw group were analyzed with a *t* test assuming unequal variance (Microsoft Excel for Mac 2016).

RESULTS

An electronic search of hospital records for patients that received an intramedullary nailing for distal tibia fractures identified 33 patients over the 2-year study period. Three patients were excluded; two had no postoperative radiographs and were not followed-up at our hospital. One patient was excluded as they underwent an exchange nailing for a nonunion.

Thirty patients were, therefore, included. Twenty patients had no blocking screw and 10 patients had a blocking screw inserted. Demographic data are described in Table 1. Ten patients

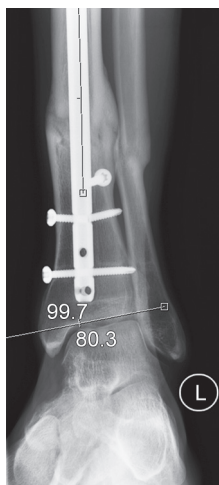


Fig. 3: An AP radiograph of the same patient taken 12 months later. It demonstrates an increase in the joint mal-orientation and a broken locking bolt

Table 1: A table summarising the group demographics

	<i>Blocking screw group</i>	<i>No blocking screw group</i>
Number of patients	10	20
Age—mean (years)	39 (range 22–61)	40 (range 17–93)
Sex—male:female	5:5	10:10
Side—left:right	7:3	10:10
Reamed:unreamed	10:0	19:1
Open:closed	2:8	2:18
Comminution—yes:no	6:4	11:9
Intra-articular—yes:no	2:8	2:18
Smoking—yes:no	2:8	2:18

had a medial para-patellar approach, seven were treated with an extrasynovial approach, eight tibial nails were inserted supra-patellar, and five through the patella tendon.

Deformity in the plane of the joints is better tolerated and only three patients had a joint orientation difference of 2° or more in the sagittal plane. Furthermore, no blocking screws were used in this plane and, therefore, no further analysis of this data was performed.

Six patients had a difference in their coronal plane joint orientation of 2° or more (range 2.0–4.7°) between their immediate postoperative radiograph and their radiograph at the latest assessment (mean follow-up of 10 months). Three patients (15%) were in the group without a blocking screw and three patients (30%) were in the group with a blocking screw. The results were analyzed with a Chi-squared test and did not reach statistical significance ($p = 0.82$).

A further analysis of the data was performed to determine if the number of distal locking bolts had a relationship with the development of a postoperative deformity. Four patients that developed a deformity had two locking bolts (two had a blocking screw) and two patients had three locking bolts (one had a blocking screw). A Chi-squared test was performed and there was no statistically significant relationship between the number of distal locking bolts and the development of a postoperative deformity ($p = 0.64$).

Twenty-five patients had achieved a RUST score of 10 at their most recent follow-up assessment. Five patients had not achieved a RUST score of 10. This was due to insufficient follow-up and they had either not attended any further follow-up (did not attend (DNA)—three patients) or had been discharged (two patients), as they were making good progress and union was anticipated (Table 2). Their data were included in the analysis of patients developing a deformity, as patients developing a deformity are less likely to self-discharge and the two patients discharged by the clinicians were asymptomatic and making satisfactory progress to union. However, their data were not included in the analysis of the time to union (RUST score greater or equal to 10).

A *t* test assuming unequal variances was used to compare the groups time to union (RUST score greater or equal to 10). The mean time to union in the blocking screw group was 8.9 months (8 patients; range 5–16 months; SD 4.2 months). In the group with no blocking screw, the mean time to union was also 8.8 months (17 patients; range 4–19 months; SD 4.4 months). The difference in the time to union was not statistically significant ($p = 0.50$ one sided and $p = 1.00$ for a two-sided *t* test).

DISCUSSION

The amount of malalignment and shortening considered acceptable is controversial.¹¹ Puno et al. demonstrated that distal tibial malalignment may be more poorly tolerated than proximal

malalignment.¹² Trafton's recommendation is generally agreed on by many authors. per Trafton's recommendation, the acceptable malalignment is less than 5° of varus–valgus angulation, 10° of anteroposterior angulation, 10° of rotation, and 15 mm of shortening.¹³ Merchant and Dietz in 1989 suggested that for distal tibial fractures, deformity of greater than 5° was associated with radiographic changes in the ankle.¹⁴

We chose a difference in the measured joint orientation of 2° or more as we felt that this was unlikely to be accounted for by an error or variation in the measurement of different radiographs. Second, a 2° or more change in ankle joint orientation is more likely to be clinically significant. Third, in the study of blocking screws in proximal and distal third tibial fractures by Krettek et al., they reported that all fractures were united with a mean loss of reduction between blocking screw insertion and fracture union of $0.5 \pm 1.7^\circ$. Of note, they used small diameter unreamed nails and the blocking screws were inserted either after nail insertion (with manual reduction) or after backing the nail out and, subsequently, reinserting the nail after screw placement.¹⁵ Finally, in our series, the mean joint orientation difference was 0.54° and the standard deviation was 1.54°; we felt that outliers above 2° were more likely to be significant.

Our study has shown that the overall incidence of fracture migration following intramedullary nailing was 20% (6/30 patients). The use of a blocking screw has not had a significant effect on the prevention of a postoperative deformity. The number of distal locking bolts has also not affected the chances of developing a postoperative deformity. However, the number of distal locking bolts is more likely to correlate with the fracture configuration, so "simpler" or more proximal fractures are likely to have fewer locking bolts and are, therefore, less likely to deform.

In a cadaveric study of a metaphyseal tibia fracture model stabilized with unreamed nails, Krettek et al. reported that the addition of two anteroposterior blocking screws decreased the deformation of the bone-implant construct by 57% compared to a construct with no blocking screws.⁵ In a separate biomechanical study to assess the addition of a blocking screw in simulated weight bearing, Chan et al. compared three distal tibia constructs fixed with reamed tibial nails: one group with a tibial nail with 2 locking bolts, one with 2 locking bolts and an antero-posterior (AR) blocking screw, and one with 3 locking bolts.¹⁶ They reported the highest axial stiffness in the 3 locking bolt construct; however, there was no evidence of permanent deformation in any of the three groups and the addition of a blocking screw did not result in a statistically significant difference in construct stiffness compared to the 2 or 3 locking bolt constructs. In our study, the addition of a blocking screw has not been shown to have any effect on the time to union or the prevention of a late deformity.

In a study by Van Dyke et al.¹⁷ looking at the effect of femoral infra-isthmal blocking screws used with a retrograde femoral nail, they found that the addition of blocking screws did not have a significant effect on the alignment between the initial postoperative radiograph and those taken at fracture union.

It is important to note that blocking screws can be associated with complications. Sengodan et al. reported a case (1/20) of a new fracture line appearing while introducing the nail after placement of the blocking screw.¹⁸ It is also recognized that the placement of a blocking screw will increase the surgical procedure time and the amount of the radiation exposure for the patient.

This study is a pragmatic, unbiased observational assessment of current clinical practice within a UK level 1 major trauma

Table 2: Outcome, deformity, and RUST scores of patients with insufficient follow-up

Patient	Outcome	Blocking screw	RUST (months)	AP difference (°)
1	DNA	Yes	8 (4)	1.6
2	Discharged	Yes	9 (5)	−0.1
3	Discharged	No	5 (1)	0.1
4	DNA	No	6 (2)	−0.8
5	DNA	No	8 (4)	0.5

center. Potential limitations are that the fractures were initially coded as distal by the operating surgeon and not by the authors. Therefore, some fractures that were coded as diaphyseal tibial fractures may have been within 2 Müller squares of the ankle joint and would have been suitable for inclusion. These were less likely to require a blocking screw being further away from the metaphyseal region and were less likely to deform; as such, the omission of these fractures may not have influenced the outcome of this study. Another potential criticism is that the follow-up was not standardized and patients were not routinely X-rayed at every postoperative clinic attendance. This was reflective of the surgeons' routine practice, a facet we did not change as this may have produced an element of bias *via* a Hawthorne effect. Finally, the study may be underpowered as the groups are quite small. Given that this subtype of fracture pattern is not very common, a multicenter study would be required to achieve a larger dataset.

CONCLUSION

This study supports our clinical practice where routine use of blocking screws is avoided. We use a 2.5-mm blocking wire to aid in fracture reduction prior to reaming or nail insertion and then remove the wire when the nail has been adequately locked. Replacement of the wire with a blocking screw is not performed and this decreases the procedure time, cost, and radiation exposure. Blocking screws are used in cases of hypertrophic nonunion, where increased bone-implant construct stability is desired, and in cases with significant metaphyseal comminution.

REFERENCES

1. Kuo LT, Chi CC, et al. Surgical interventions for treating distal tibial metaphyseal fractures in adults. *Cochrane Database Syst Rev* 2015;30(3):CD010261. DOI: 10.1002/14651858.CD010261.pub2.
2. Vallier HA. Current Evidence: Plate vs Intramedullary Nail for Fixation of Distal Tibia Fractures in 2016. *J Orthop Trauma* 2016;30(Suppl. 4):S2–S6. DOI: 10.1097/BOT.0000000000000692.
3. Mao Z, Wang G, et al. Intramedullary nailing vs plating for distal tibia fractures without articular involvement: a meta-analysis. *J Orthop Surg* 2015;10:95. DOI: 10.1186/s13018-015-0217-5.
4. Zelle BA, Bhandari M, et al. Treatment of distal tibia fractures without articular involvement: a systematic review of 1125 fractures. *J Orthop Trauma* 2006;20:76–79. DOI: 10.1097/01.bot.0000202997.45274.a1.
5. Krettek C, Miclau T, et al. The mechanical effect of blocking screws ("Poller screws") in stabilizing tibia fractures with short proximal or distal fragments after insertion of small-diameter intramedullary nails. *J Orthop Trauma* 1999;13:550–553. DOI: 10.1097/00005131-199911000-00006.
6. Kulkarni SG, Varshneya A, et al. Intramedullary Nailing Supplemented with Poller Screws for Proximal Tibial Fractures. *J Orthop Surg* 2012;20:307–311. DOI: 10.1177/230949901202000308.
7. Stinner DJ, Mir H. Techniques for Intramedullary Nailing of Proximal Tibia Fractures. *Orthop Clin North Am* 2014;45:33–45. DOI: 10.1016/j.jocl.2013.09.001.
8. Paley D. Principles of Deformity Correction. Berlin, New York: Springer, 2002.
9. Whelan DB, Bhandari M, et al. Development of the radiographic union score for tibial fractures for the assessment of tibial fracture healing after intramedullary fixation. *J Trauma* 2010;68:629–632. DOI: 10.1097/TA.0b013e3181a7c16d.
10. Panjabi MM, Walter SD, et al. Correlations of radiographic analysis of healing fractures with strength: a statistical analysis of experimental osteotomies. *J Orthop Res Off Publ Orthop Res Soc* 1985;3:212–218. DOI: 10.1002/jor.1100030211.
11. Pynsent PB, Fairbank JCT, et al. Outcome measures in orthopaedics and orthopaedic trauma, 2nd ed. London, New York: Arnold; Distributed in the United States by Oxford University Press, 2004.
12. Puno RM, Vaughan JJ, et al. Long-term effects of tibial angular malunion on the knee and ankle joints. *J Orthop Trauma* 1991;5:247–254. DOI: 10.1097/00005131-199109000-00001.
13. Canale ST, Beaty JH, et al. Campbell's operative orthopaedics, 12th ed. London: Mosby, St. Louis, Mo., 2012.
14. Merchant TC, Dietz FR. Long-term follow-up after fractures of the tibial and fibular shafts. *J Bone Joint Surg Am* 1989;71:599–606. DOI: 10.2106/00004623-198971040-00016.
15. Krettek C, Stephan C, et al. The use of Poller screws as blocking screws in stabilising tibial fractures treated with small diameter intramedullary nails. *J Bone Jt Surg Br* 1999;81:963–968. DOI: 10.1302/0301-620X.81B6.10000.
16. Chan DS, Nayak AN, et al. Effect of distal interlocking screw number and position after intramedullary nailing of distal tibial fractures: a biomechanical study simulating immediate weight-bearing. *J Orthop Trauma* 2015;29:98–104. DOI: 10.1097/BOT.0000000000000195.
17. Van Dyke B, Colley R, et al. Effect of blocking screws on Union of Intraisthmus Femur Fractures Stabilized With a Retrograde Intramedullary Nail. *J Orthop Trauma* 2018;32:251–255. DOI: 10.1097/BOT.0000000000001119.
18. Moongilpatti Sengodan M, Vaidyanathan S, et al. Distal Tibial Metaphyseal Fractures: Does Blocking Screw Extend the Indication of Intramedullary Nailing? *ISRN Orthop* 2014;2014:1–7. DOI: 10.1155/2014/542623.